

INTRAOPERATIVE LOCALIZATION USING SAVI SCOUT® TECHNOLOGY FACILITATES RESECTION OF NON-PALPABLE TRUNK AND EXTREMITY SARCOMA

Kristy Kummerow Broman, David Joyce, Odion Binitie, Douglas Letson, Ricardo Gonzalez, John Mullinax



H. LEE MOFFITT CANCER CENTER
TAMPA, FLORIDA

BACKGROUND & METHODS

Non-palpable soft tissue sarcomas can be difficult to locate intraoperatively

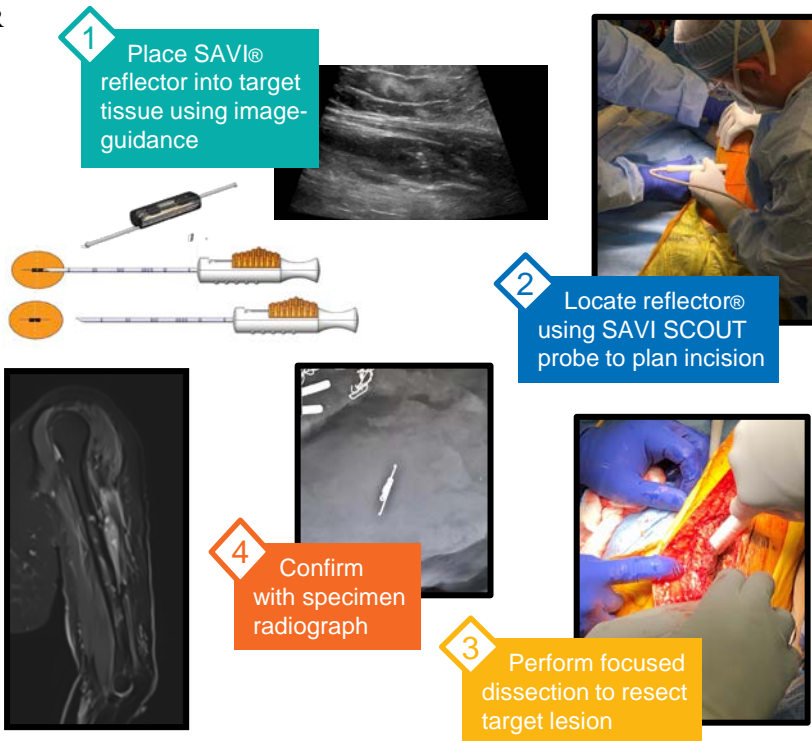

SAVI SCOUT® localization device

- Uses radar technology
- Widely used in breast surgery
- FDA-approved for soft-tissue tumors

Retrospective case series (N=10)
Trunk and extremity sarcoma resected using SAVI SCOUT®

CASE:

70-year old female with undifferentiated spindle cell sarcoma of left upper arm, recurrent after resection and radiation



RESULTS

- 8 resections for recurrent disease (7 with prior radiation)
- 2 resections after neoadjuvant chemo
- One local recurrence
- Three patients with distant metastases
- Remainder with no evidence of disease at median follow-up of 14 months

CONCLUSIONS

SAVI SCOUT® facilitated resection in all cases attempted

Applicable to:

- Recurrent disease
- Irradiated fields
- Neoadjuvant therapy cases