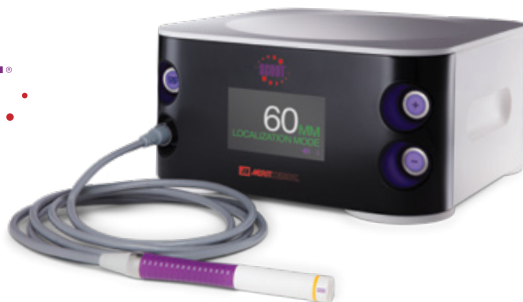



Specimen Assessment with SCOUT® Distance Measurement

Rie Aihara, MD

Medical Director, Surgical Breast Oncologist
Regional Breast Care, Ft. Myers, FL

Patient: 66-year-old female

Preoperative Diagnosis: Ductal Carcinoma In Situ

Postoperative Diagnosis: Invasive ductal carcinoma and DCIS, T1, N0, M0 Stage 1

Procedure: Left breast SCOUT® localized partial mastectomy for DCIS

Patient History

The patient is a 66-year-old caucasian female with a family history of breast cancer. Annual screening mammogram revealed a new cluster of microcalcifications in the 3 o'clock position of the left breast, and a stereotactic biopsy was performed. Post-biopsy imaging confirmed the presence of a well-positioned clip and pathology revealed a low-grade ductal carcinoma in situ with an ER/PR positive status. Preoperative MRI showed closely approximated 1.3 cm and 0.6 cm areas of abnormal mass enhancement related to the biopsy clip within the upper outer quadrant of the left breast corresponding to her biopsy proven DCIS with no other areas of suspicious enhancement in either breast. She elected to undergo breast conservation therapy and a SCOUT® localized partial mastectomy was performed.

Procedure

The patient underwent a mammography-guided SCOUT reflector placement one week prior to surgery. On the day of surgery, using the post reflector placement mammogram and the SCOUT system as guidance, the reflector was identified at the 3 o'clock position in the lateral aspect of the left breast. A transverse incision was made over the strongest obtained signal. Upon entering the subcutaneous tissue, the distance to the reflector was measured to be 5-6 mm using the SCOUT console. Using the guidance of the handpiece from all sides of the target, a partial mastectomy was performed. The excised specimen, once labeled with orientation sutures, was evaluated using the SCOUT system by recording the distance from each margin to the reflector (see table).

The approximate specimen size was 3 x 3 x 2 cm. Radiographic evaluation confirmed the presence of the biopsy clip and reflector within the specimen. Based on imaging and the distance analysis, the reflector appeared closest to the inferior and anterior margins (see Figure 1). Additional margins were thus taken for safety.

Margin	Margin-to-reflector distance
Anterior	1 mm*
Inferior	3 mm*
Posterior	11 mm
Superior	7 mm
Lateral	13 mm
Medial	9 mm

*Additional margins taken

Pathology

In addition to the known DCIS, two small foci of grade 2 invasive ductal carcinoma measuring 8 mm and 5 mm were found on final pathology. Both of these tumors were noted to be ER/PR positive, and HER-2 negative with genomic low risk of recurrence. The closest margins were anterior and inferior at 4 mm.

Because of her invasive component, the patient did return to the operating room for sentinel lymph node assessment with analysis of 2 lymph nodes that were negative. She proceeded with radiation therapy and endocrine therapy.

Conclusion

The inability to visualize the marking clip, localizing devices or the actual tumor intraoperatively renders it difficult to estimate the amount of tissue present between the target and the margins. The SCOUT distance system in this case allowed for an objective measurement of the reflector to the margin. Final pathology confirmed the distance to be accurate. Surgeons rely on specimen imaging to guide the decision to take additional tissue based on visual proximity, however, the SCOUT system provided an additional objective measurement to help guide decision making intraoperatively to minimize the need for return to the operating room.

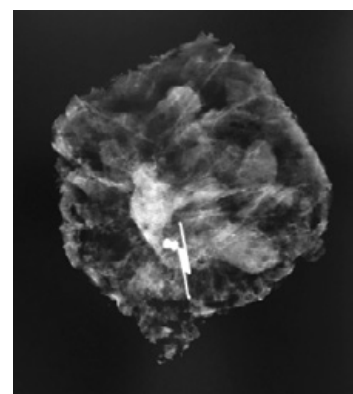


Figure 1: Showing specimen radiograph, SCOUT reflector and biopsy clip.



ciannamedical.com/savi-scout
merit.com

The foregoing case and other information are for the practitioner's convenience and for general information purposes only. This information does not constitute medical or legal advice, nor is it meant to endorse or guarantee the suitability of any of the referenced products or methods for any specific patient or procedure. Before using any product, refer to the Instructions for Use (IFU) for indications, contraindications, warnings, precautions, and directions for use.