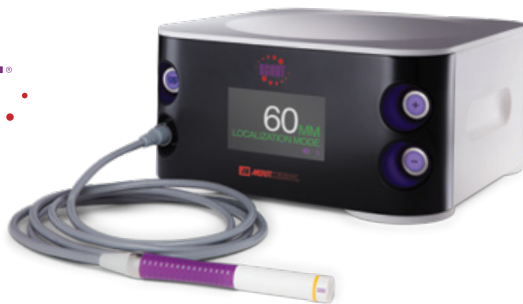



# Inguinal Lymph Node Marked with SCOUT® Following Melanoma Surgery

## Freddie Combs, MD

Director of Breast Imaging

Pacific Breast Center, Costa Mesa, CA

## Maki Yamamoto, MD

Surgical Oncologist – Melanoma and Soft Tissue Sarcoma

UCI Health Chao Cancer Center, Orange, CA

**Patient:** 69-year-old male

**Diagnosis:** Lymphadenopathy

**Rx:** Right inguinal lymph node excision

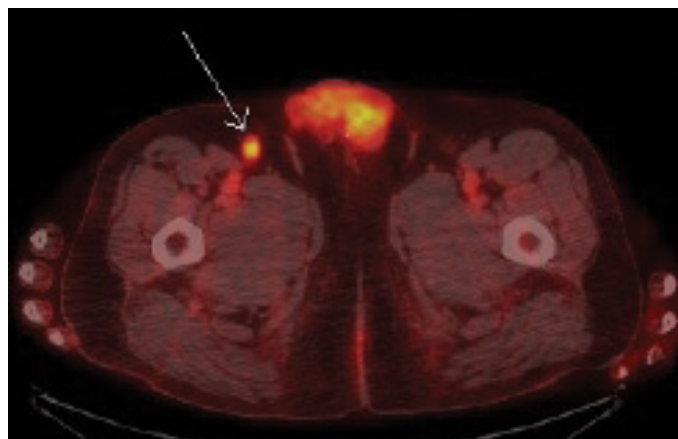
**Challenge:** Localization and excision of a non-palpable inguinal lymph node using SCOUT®

### Patient History

A 69-year-old male with a history of left arm melanoma status post excision in May 2017 presents with new right inguinal adenopathy on PET scan in May 2018. Ultrasound confirmed an abnormal morphology inguinal lymph node. Biopsy of the node was suggestive of Lymphoma and node excision was recommended.

### Reflector Placement

SCOUT was recommended for localization due to ease of placement, ability to place the reflector at any time prior to surgery and improved surgical accuracy. For the procedure, the patient was placed in the supine position and the target right inguinal lymph node was identified with ultrasound. The area was prepped and anesthesia administered via 1% lidocaine injection. A SCOUT reflector was then placed within the target lymph node. The reflector was then easily identified with the SCOUT system. A mark was placed on the skin over the target area. Reflector placement occurred 9 days prior to the surgical excision.



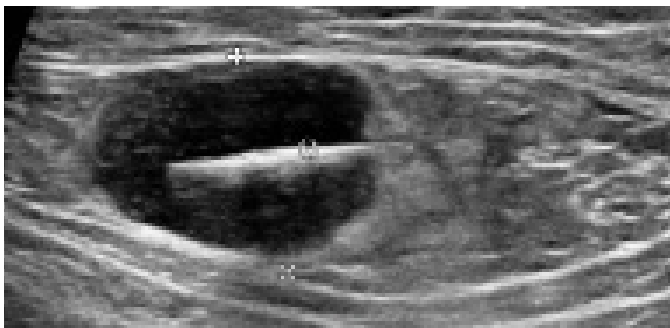
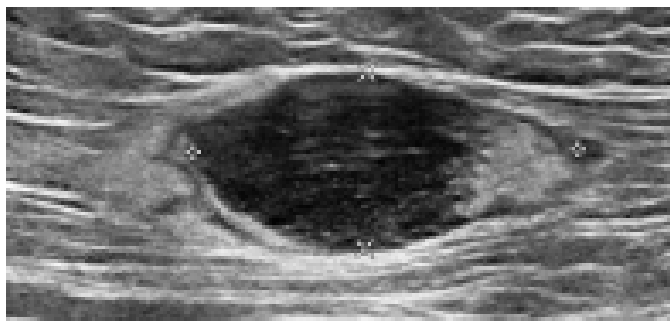
PET Scan of inguinal lymph node

### Surgery

The patient was taken to the operative suite and monitored anesthesia care was administered. The right inguinal operative site was prepped and draped. The SCOUT system was utilized to identify the reflector signal within the target lymph node in the right inguinal region. Surgical incision was made and the node was excised using the SCOUT system for guidance. Upon excision, the accuracy of excision was confirmed using the SCOUT Guide on the surgical specimen.

### Pathology

Surgical pathology shows Follicular Lymphoma, low grade. The immediate post-operative course was uncomplicated.



Pre and Post placement ultrasound images

### Conclusion

Use of SCOUT for localization in soft tissue is highly effective based upon ease of placement and surgical accuracy. In this case, SCOUT localization resulted in accurate surgical excision of a malignant inguinal lymph node. The system performed well in inguinal soft tissue and will be utilized in similar cases in the future at our institution.



[ciannamedical.com/savi-scout](http://ciannamedical.com/savi-scout)  
[merit.com](http://merit.com)

The foregoing case and other information are for the practitioner's convenience and for general information purposes only. This information does not constitute medical or legal advice, nor is it meant to endorse or guarantee the suitability of any of the referenced products or methods for any specific patient or procedure. Before using any product, refer to the Instructions for Use (IFU) for indications, contraindications, warnings, precautions, and directions for use.